

CASE REPORT

Side effects of occlusal guides and challenges during Orthodontic treatment

Sangsuwon C^a, DeMaio V^a, Teixeira CC^a, Alikhani M^{a,b}

a CTOR Academy, Hoboken, New Jersey

b Harvard University, Department of Developmental Biology, Boston, Massachusetts

Corresponding Author:

Mani Alikhani
mani.alikhani@ctor.academy

Citation: Sangsuwon C, DeMaio V, Teixeira CC, Alikhani M. Side effects of occlusal guides and challenges during Orthodontic treatment. *Innovation*. 2026;4(1):1-11. <https://doi.org/10.30771/2026.1>

Submitted April 13, 2026

Accepted May 15, 2026

Keywords: Class II occlusion, Skeletal deformity, Non-surgical treatment, Suture, Cortical Drifting, Open-bite, External plate, Adult, Orthopedic, Orthodontic

ABSTRACT

Long-term use of oral appliances (splints) can irreversibly alter the occlusal relationship between the jaws. This is more common if the appliance does not cover all the teeth. One such appliance is a splint used to treat temporomandibular dysfunction (TMD) by disoccluding the posterior teeth or advancing the mandible. Long-term use of these appliances can lead to the development of a severe anterior open bite. In a patient with mandibular deficiency, this effect is even more devastating, as it can also lead to clockwise mandibular rotation, which can significantly exaggerate the jaw deficiency and pose esthetic challenges, as well as significantly affect function, such as cutting, chewing, and speech. In addition, a change in occlusal position may alter muscular activity and loading patterns in the temporomandibular joint (TMJ), in the long term worsening TMD symptoms rather than reducing them. In this context, we present an adult patient with mandibular deficiency who has gradually developed an anterior open bite due to the long-term use of an anterior bite plate device prescribed to address TMD discomfort. She seeks orthodontic treatment due to TMD, reduced ability to cut food, speech impairment, and poor smile esthetics. The clinical exam demonstrated an open bite that was extended from the upper right first premolar to the upper left second premolar. In addition, posterior interferences at the molars caused a shift of the mandible toward the right side. In this article, we aim to raise awareness of the serious side effects of unsupervised splint therapy and to discuss how orthodontic treatment with CTOR external plates is a viable option for addressing the esthetic and functional problems of a severe iatrogenic malocclusion caused by appliances that interfere with occlusal function.

Background

Splints are oral appliances prescribed by dentists to address TMD symptoms, tension-induced headaches, excessive tooth wear, and other side effects of bruxism [1, 2]. Clinical research has demonstrated that the majority of the beneficial effects of these appliances can be attributed to their ability to reduce muscular activity, especially sleep bruxism [3, 4]. However, placebo effects have also been reported [5, 6]. Many still believe that the effect of these appliances is due to unloading of the condyle, which has not been scientifically proven [7-9].

Due to the diversity of opinions on the splint mechanism of action, many designs have been proposed, including stabilizing splints, anterior bite plates, mini-anterior bite plates, anterior repositioning appliances, posterior bite plates, pivot appliances, and hydrostatic appliances [10-13].

While all these designs can be made from hard acrylic or soft plastics [14], one of the main differences between them is the number of teeth that they cover. In situations where an oral appliance does not cover all occlusal surfaces, such as a mini-anterior bite plate used in this case report, the possibility of posterior tooth overeruption exists, which can permanently alter the occlusal relationship between the jaws.

Here we present an adult female patient who was referred to our clinic due to a severe open bite developed over a few years and extended from the upper right first premolar to the upper left second premolar. The patient reported using a mini-anterior bite plate to address the muscle tension and TMD symptoms that she developed due to bruxism. The patient presented with a Class II skeletal pattern, mandibular deficiency, and a constricted maxilla. The patient also reported that her oral function, such as cutting and chewing, was significantly compromised, a common finding in open-bite cases. Due to a lack of articulation of anterior teeth, the patient's speech was also affected, as previously reported for open bite cases [15].

The design of the mini-anterior bite plane appliance allows overeruption of the unopposed posterior teeth, resulting in an anterior open bite. This possibility increases with prolonged, continuous use, as observed in this patient. While clockwise mandibular rotation due to the eruption of posterior teeth worsened the class II relation, occlusal interference shifted the mandible to the right side, further exaggerating the class II relation on that side. Interestingly, while initially these appliances help to reduce TMD symptoms, the long term overuse of the appliance can increase TMJ loading and exacerbate TMD symptoms. Overall, this patient reported a significant reduction in her quality of life.

Historically, orthognathic surgery was the main treatment option for severe open-bite malocclusions, widely criticized for its extensive side effects and out-of-pocket costs [16]. In addition, recent research do not support longer-term stability of surgical treatments when compared to non-surgical approaches [17, 18].

Closing an open-bite through non-surgical means relies on a combination of intrusion of posterior teeth and extrusion and/or retroclination of the anterior teeth. This can be quite challenging, and oftentimes, absolute anchorage in the form of temporary anchorage devices (TADs), is needed. TADs are essential devices in orthodontics mechanotherapy and have been proven effective in providing the bone anchorage necessary to intrude maxillary posterior segments. However, TADs are only effective if they remain stable at their insertion sites during treatment. Many factors contribute to TAD's stability, including the bone density and the thickness of the cortical bone at the placement site [19]. Unfortunately, density of the alveolar bone can vary significantly in the oral cavity, and clinicians often find bone with adequate density far from the areas where they want to apply the forces. In addition, dental root proximity can significantly compromise TAD stability, along with other anatomical limitations such as the depth of the sulcus and a lack of proper width of attached gingiva.

To overcome this challenges, external plates are among the preferred tools allowing TAD placement in areas with adequate bone density, while mechanically redirecting the force to the desired area. In addition, external plates can be installed far from the teeth and in areas with few anatomical limitations or risk of trauma to the dental roots. The convenience of distant bone placement and their versatile design options make them an excellent tool for patients with open bites [20]. In this case report, we used the CTOR Intrusion Plate to control the posterior vertical dimension of the maxilla and correct the occlusal plane angle. Our treatment restored the patient's esthetics and function, and reduced TMD symptoms resulting in a significant improvement in quality of life.

Patient Presentation, Etiology and Diagnosis

A healthy 43-year-2-month-old female presented to our clinic with the chief concern that she felt her bite had changed after several years of using an oral appliance (splint) prescribed by her general dentist. The patient reported that she originally did not have an open bite, but now experienced difficulty biting and chewing food due to the lack of occlusal contacts. Extraoral examination and review of frontal portrait photographs (Figure 1) demonstrated a mesofacial pattern. Notable findings included mild facial asymmetry with rightward chin deviation, mild mentalis strain upon closing, and no lip incompetence at rest.

The profile photographs (Figure 1) revealed a convex facial profile, with lower lip slightly retruded relative to the E-line. The smiling portrait shows a straight smile line with virtually no buccal corridor showing. Upon smiling, the patient shows 60% of her maxillary incisors, with no gingiva displayed. No facial or occlusal cants were observed.

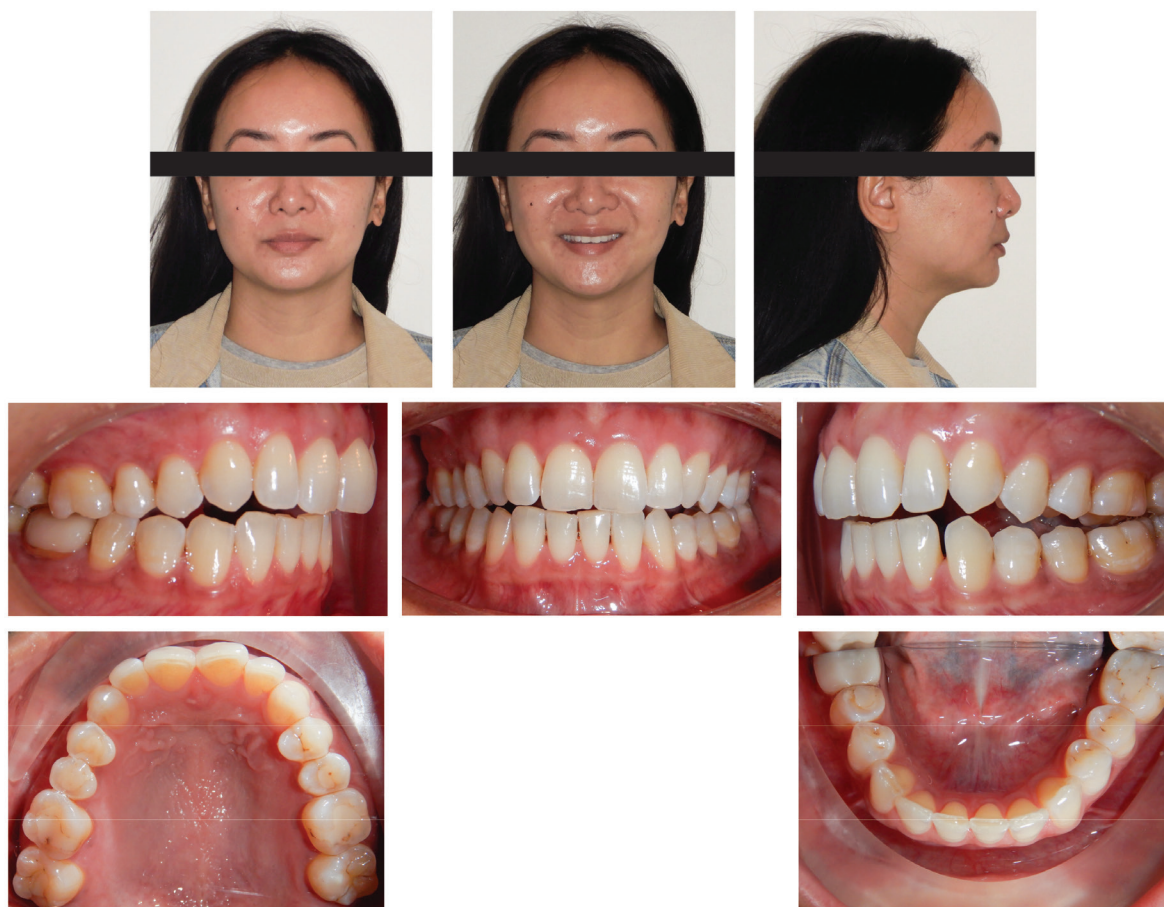


Figure 1: Pre-treatment portrait and intra-oral photographs. Frontal and profile views demonstrate a mesofacial pattern with a convex profile. Notable findings include mild facial asymmetry with the chin deviated to the right side and mild mentalis strain upon closing. The smiling portrait reveals a straight smile line with minimal buccal corridors and 60% maxillary incisor display, with no gingival display. The maxillary midline is coincident with the facial midline, while the mandibular midline is deviated 3 mm to the right. The maxillary arch is constricted and asymmetrical, resulting in an edge-to-edge relationship in the molar regions. Dental relationships show a full-cusp Class II on the right side and an end-on Class II on the left. A severe asymmetrical overjet (2 to 4 mm) is present, being more pronounced on the right side. An anterior and posterior open bite is observed, ranging from -1 to -4 mm from the upper right first premolar to the upper left second premolar. Multiple restorations are present, including a crown on the lower right first molar. Gingival recession is noted on the lower right second premolar and lower left lateral incisor.

Digital cast analysis showed a full-cusp Class II molar and canine relationship on the right side and an end-on Class II molar and canine relationship on the left side, and a pronounced open bite, ranging from -1 to -4 mm from the upper right first premolar to the upper left second premolar. The upper arch was constricted in the area of the molars and asymmetrical. An asymmetrical overjet of 2-4 mm was also observed, greater on the left side. The mandibular arch showed a moderate curve of Spee and curve of Wilson.

The panoramic radiograph (Figure 2) exhibited a complete dentition of 28 erupted permanent teeth and two impacted mandibular third molars. The roots of all teeth were fully developed, but there were signs of blunting on the maxillary second premolars. Remodeling of the condyles was also observed.

Lateral cephalometric analysis (Figure 3 and Table I) revealed a skeletal Class II relation ($ANB = 5.7^\circ$, $WITS = 3.2\text{mm}$) with a retruded mandible ($SNB = 74.7^\circ$). The inclinations of the maxillary incisors was reduced, while mandibular incisors presented normal inclination ($U1^\circ - SN = 92.5^\circ$, $IMPA = 93^\circ$). In addition, cephalometric analysis demonstrated counterclockwise rotation of the upper occlusal plane and clockwise rotation of the mandible.

The panoramic radiograph did not show a crown on the lower right second premolar, whereas the lateral cephalometric radiograph subsequently reveals the presence of a crown on this tooth. This discrepancy reflects the chronological sequence of imaging: the panoramic radiograph was obtained before crown placement, and the cephalometric radiograph was obtained after the prosthodontic restoration was completed.

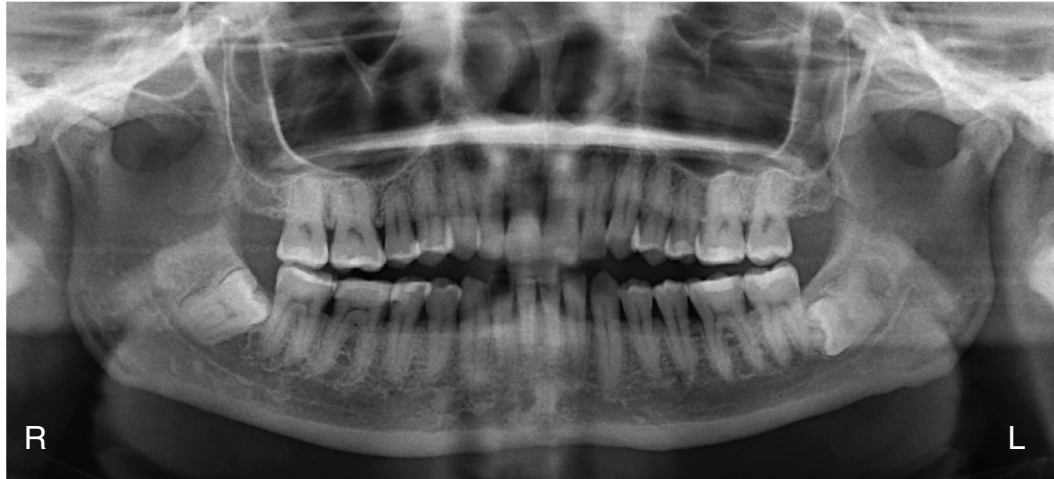

Figure 2: Pre-treatment panoramic radiograph. The panoramic radiograph reveals a complete dentition with 28 erupted permanent teeth and two impacted mandibular third molars. The roots of all teeth are fully developed, but there were signs of blunting on the maxillary second premolars. Remodeling of the condyles was also observed.

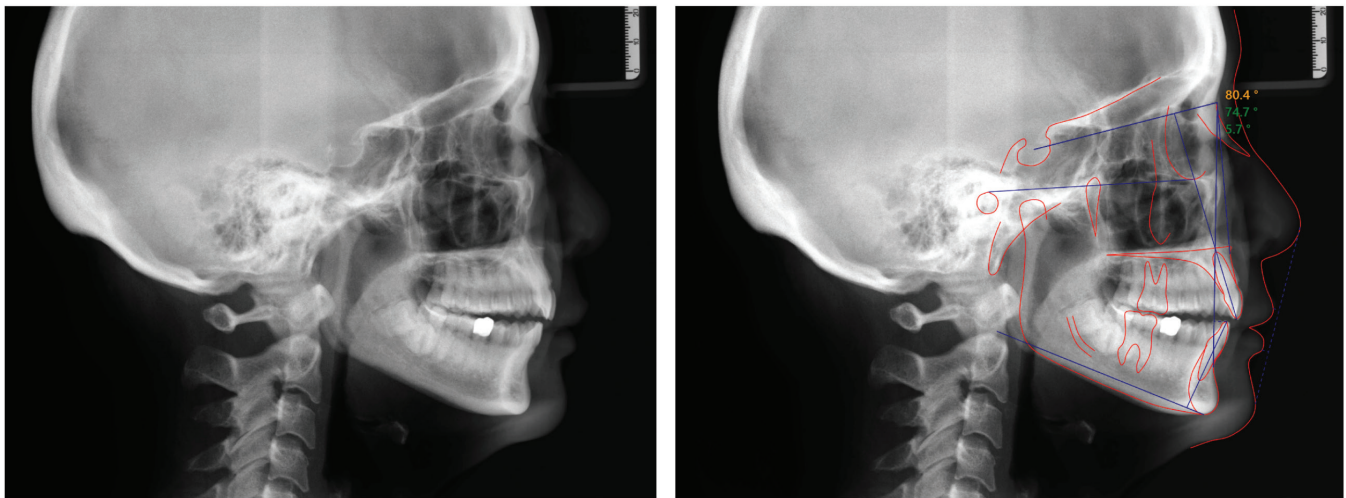


Figure 3: Pre-treatment lateral cephalometric radiograph. Pre-treatment lateral cephalometric radiograph shows a skeletal Class II jaw relation with counterclockwise rotation of the mandible and a retrognathic mandible. The maxillary incisors were slightly retroclined. The upper occlusal plane demonstrated counterclockwise rotation. Soft-tissue analysis indicated that the lower lip was slightly retruded. A crown was placed on the lower second premolar before initiation of treatment.

Treatment Objectives

The primary treatment objective was to address the patient’s chief complaint by closing the open bite, to establish a functional and stable occlusion, and improve facial and dental esthetics. More specifically, the objectives included the following:

I. Facial Esthetics: Improve profile by improving the lower lip position relative to the E-plane, and correct the mandibular shift to increase facial symmetry.

II. Skeletal Objectives: Reduce clockwise rotation of the mandible and correct the rightward shift to reduce the Class II skeletal relationship and improve skeletal symmetry.

III. Dental Objectives: Correct the open bite, expand the upper arch while maintaining the lower arch’s transverse dimension, improve the occlusal plane angle, and alleviate crowding in both the upper and lower arches. Improve the maxillary incisors’ inclination and retrocline the mandibular incisors. Establish Class I molar and canine relationships and coordinate the posterior bucco-lingual occlusal relations.

Treatment Options

The patient was presented with multiple treatment options. The patient declined the surgical option to address the skeletal problems. To address her open bite, therefore, we offered a non-surgical approach using both CTOR external plate and fixed appliances.

Mechanotherapy Plan and Treatment Duration

We initiated treatment with fixed appliances, bonded to the maxillary posterior teeth to expand the dental arch with a continuous arch wire bypassing the anterior teeth, followed by a full setup of mandibular teeth, and later on all maxillary teeth. The CTOR external plate was placed using two palatal TADs (psm-medical.com). Once installed, buttons were bonded to the lingual surfaces of the upper 5's, 6's, and 7's, and power threads were engaged from the lingual surface of each tooth to the arms of CTOR plate to intrude posterior teeth. This improved the occlusal plane and mandibular plane angle, as well as the dental Class II skeletal and dental relation. In addition, occlusal interferences were correct and occlusal contacts gradually balanced to prevent mandibular shift to the right, which further improved the molar and canine relations and corrected the asymmetric overjet. The total treatment duration was 28 months.

Treatment Outcome

I. Facial and Soft Tissue analysis

The patient's overall facial balance improved with treatment as evidenced by improved lower lip position, a labiomental angle that increased from 98° to 132°. Initially, the patient had mentalis strain, which is no longer present post-treatment. Correction of mandibular shift eliminated the facial asymmetry (Figure 4).

II. Smile analysis

The patient showed improved incisor display with coincidental midlines upon smiling. Correction of the open bite also significantly improved smile esthetics. Gingival display evaluation showed leveling of the gingival margins and the heights of contour of anterior teeth.

III. Intra-oral Photographs and Digital Cast analysis

Intra-oral photographs and cast analysis showed the following outcomes (Figure 4):

- A) The open bite was corrected, and normal overjet (2 mm) and overbite (2.5 mm) relations were established.
- B) All posterior teeth are now in occlusion with occlusal contacts evenly distributed.
- C) Both the maxillary and mandibular dental midlines were aligned with the facial midline, and the mandibular shift corrected.

Measurement	Initial Value	Final Value	Norm
SNA (deg)	80.4°	80.2°	81.8 ± 3.7°
SNB (deg)	74.7°	76.2°	79.2 ± 2.3°
ANB (deg)	5.7°	4°	2.6 ± 2.4°
WITS Appraisal (mm)	3.2	-1.1	-0.1 ± 1.77
FMA (deg)	28.5°	25.1°	25.8 ± 3°
SN-MP (deg)	36.4°	31.2°	31.2 ± 3°
Maxillary Incisor to SN (deg)	92.5°	92.8°	102.4 ± 5.5°
IMPA (deg)	93°	91.3°	92.1 ± 9°
Maxillary Incisor to NA (mm)	0.4 mm	0.7 mm	3.8 ± 2.7 mm
Mandibular Incisor to NB (mm)	4.4 mm	3.7 mm	3.4 ± 3.6 mm
Upper Lip to E-Plane (mm)	-2.2 mm	-1.5 mm	-2 ± 2 mm
Lower Lip to E-Plane (mm)	-2.8 mm	-1 mm	-2 ± 2 mm

Table I: Cephalometric Analysis Pre- and Post-treatment. Angular and linear measurements were completed between craniofacial skeletal, dental, and soft tissue landmarks identified on pre- and post-treatment lateral cephalograms (° - degrees, mm - millimeters). Table shows initial and final values for this patient as well as expected normal values (Norm).

- D) Maxillary and mandibular crowding was eliminated.
- E) Class I canine and molar occlusion relation was established.
- F) The patient demonstrated cuspid-rise and a mutually protected occlusion. No pain or clicking was reported or observed in either TMJ.

IV. Panoramic Radiograph Analysis

Post-treatment panoramic radiograph (Figure 5) showed root parallelism. Upper premolars’ root blunting remains unchanged from the beginning of treatment.

V. Cephalometric Analysis

Pre-treatment and post-treatment comparison of lateral cephalometric analyses (Table I and Figure 6) demonstrates significant improvement in the maxillary and mandibular sagittal skeletal relationship, with the ANB angle and WITS

decreasing from 5.7° to 4° and 3.2mm to -1.1 mm, respectively. The skeletal vertical dimension improved as shown by a change in FMA from 28.7° to 25.1° and SN-MP from 36.4° to 31.2°. Maxillary anterior teeth inclination was maintained (U1-SN from 92.5° to 92.8°) while the mandibular anterior teeth were slightly retroclined (IMPA from 93° to 91.3°)

There was improvement in lip position, especially lower lip (upper lip to E-plane = -2.2 mm and lower lip to E-plane = -1.2 mm)

The cranial base superimposition of pre- and post-treatment lateral cephalograms showed a counter-clockwise rotation of the mandible. Maxillary superimposition showed the intrusion of the upper molars and extrusion and slightly proclination of the upper anterior teeth (Figure 7). The mandibular superimposition revealed protraction of the lower molars and extrusion of the mandibular anterior teeth (Figure 8).

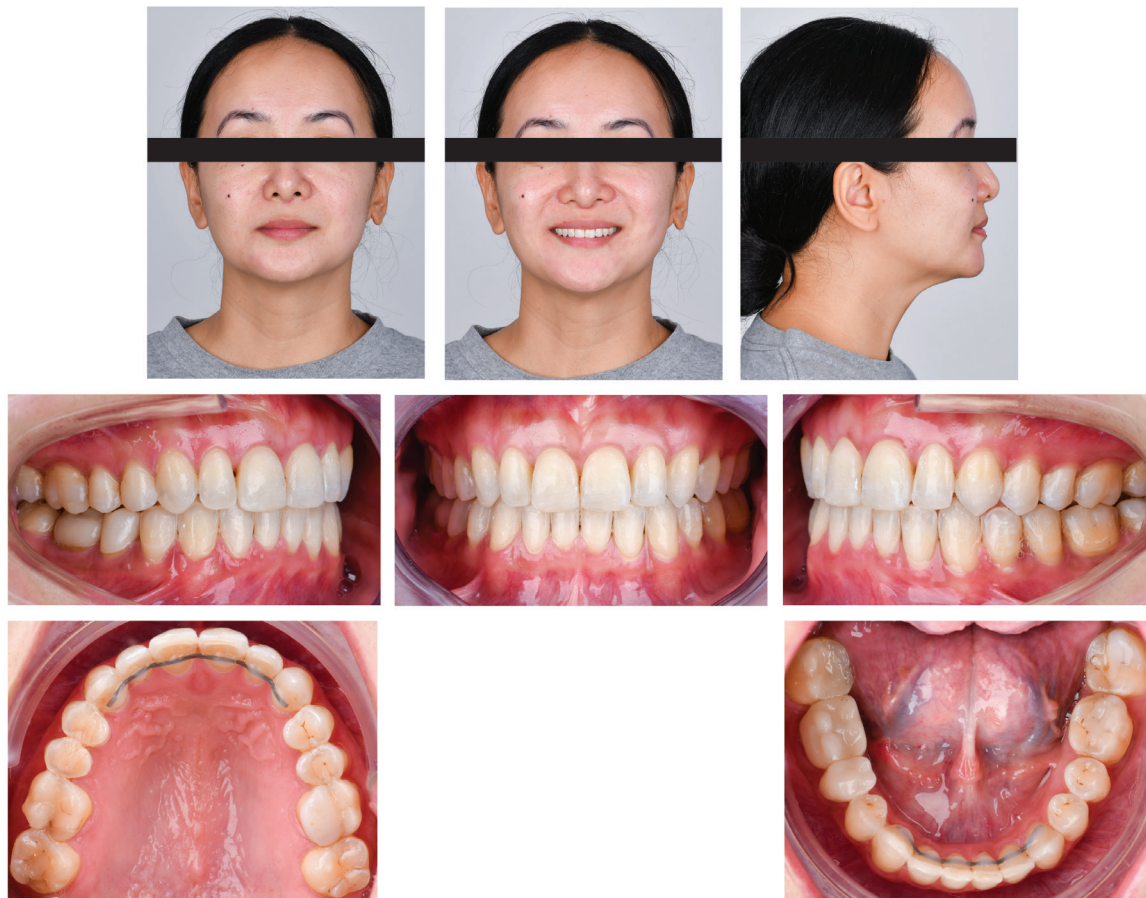

Figure 4: Post-treatment portrait and intra-oral photographs. Post-treatment photographs show a significant improvement in facial vertical dimension and profile through mandibular counter-clockwise rotation and correction of the mandibular shift, resulting in harmonized facial symmetry. The profile convexity and mentalis strain were successfully resolved, with an improved labiomental angle. Smile aesthetics were enhanced by correcting the open bite, achieving proper incisor display coincident with the smile line, and leveling the gingival margins. Intraorally, the patient presents a stable Class I canine and molar occlusion, corrected dental midlines aligned with the facial midline, and successful dental alignment. A normal overjet of 2 mm and overbite of 2.5 mm were established, with all posterior teeth in ideal and evenly distributed occlusion. Functional assessment confirms a mutually protected occlusion with cuspid-rise guidance and a healthy, asymptomatic temporomandibular joint.

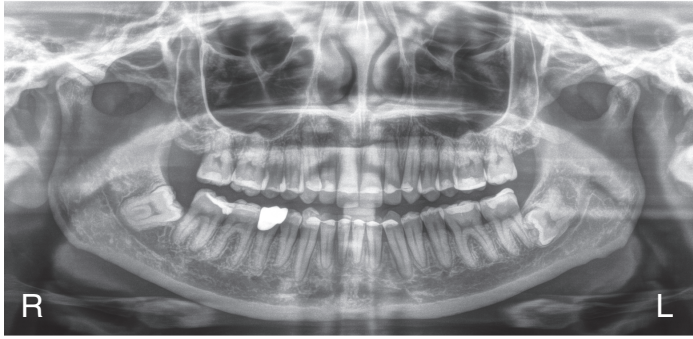


Figure 5: Post-treatment panoramic radiograph. Panoramic radiograph at the end of treatment showed good root parallelism. Upper second premolars root blunting remains unchanged from the beginning of treatment.

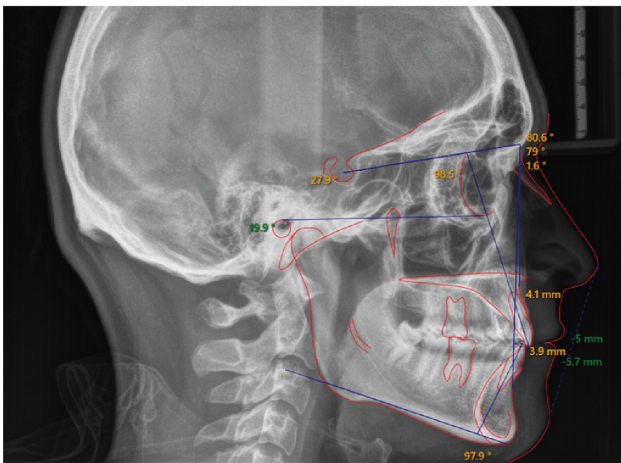
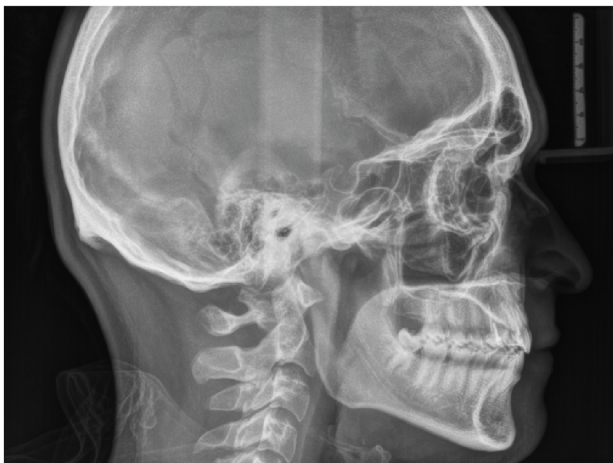

Figure 6: Post-treatment lateral cephalometric radiograph. Post-treatment cephalometric radiograph demonstrates a significant improvement in the sagittal skeletal relationship, with counterclockwise rotation of the mandible and clockwise rotation of the occlusal plane. Sagittal and vertical relation of the mandible in comparison with the maxilla significantly improved. Regarding dental inclinations, the maxillary anterior position was maintained while the mandibular incisors were slightly retroclined. These skeletal and dental changes significantly enhanced the soft-tissue profile, particularly the lower lip position.

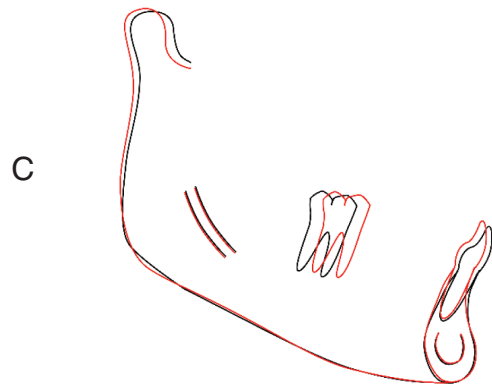
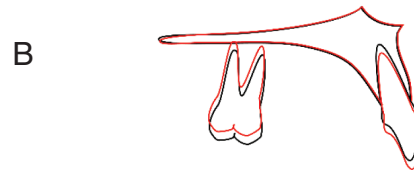
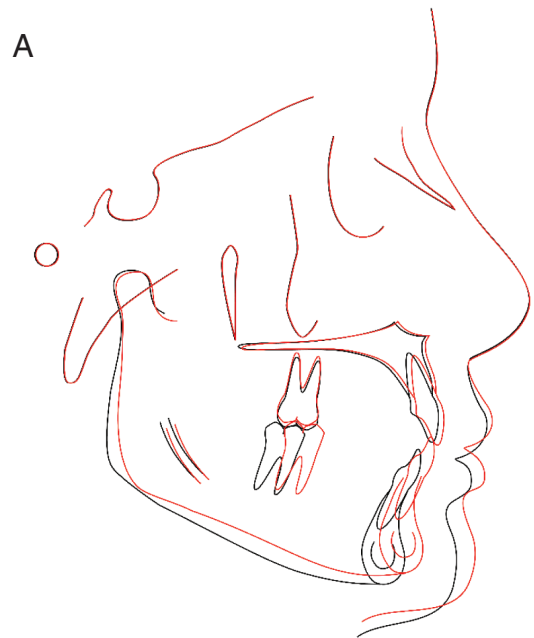

Figure 7: Superimposition of pre- and post-treatment cephalometric tracings. Cephalometric superimposition of pre-treatment (black tracing) and post-treatment (red tracing) on the anterior cranial base shows counter-clockwise rotation of the mandible and Class I jaw relation (A). Superimposition on the body of the maxilla shows maxillary incisor extrusion and maxillary molar intrusion (B). Superimposition based on the inferior-alveolar nerve and inner profile of the mandibular symphysis reveals mesialization of lower molar and uprighting incisor positions (C).

Discussion

One of the common appliances dentists recommend to address TMD, sleep bruxism, and headaches is the mini-anterior bite plate. These mini-anterior bite plates can be custom-made or available in prefabricated formats under different names, such as the Nociceptive Trigeminal Inhibition Tension Suppression System (NTI), the Best Bite, and the Anterior Midline Point Stop (AMPS) devices [21-24]. Since these appliances disocclude the posterior teeth, if used for a long time without supervision, they can cause significant eruption of the posterior teeth, leading to an anterior openbite with esthetic and functional consequences, and a significant impact on the patient's daily life.

How can we address a severe malocclusion caused by these oral appliances? Since the etiology of anterior open bite in these cases is extrusion of posterior teeth, the focus of treatment should be intrusion of these teeth. Surgical approaches can be considered significantly invasive for reversing the iatrogenic changes caused by these appliances. On the other hand, the use of fixed orthodontic appliances alone requires complex mechanics that can be uncomfortable and require significant patient cooperation. The use of TADs, on the other hand, can be a great alternative for the treatment of an open bite case [25]. TADs can be placed bilaterally on the palatal or buccal side, usually between the first and second molars (if third molars are not present), and the intrusion force can be directly applied to the teeth or the wire that connects the teeth. However, for

the TAD application to be successful, it requires good bone density and adequate cortical bone to ensure TAD stability. In the event that bone density is low, as was the case with the patient in this case report, placement of a TAD in the alveolar bone, buccal or palatal, is not possible [26, 27]. For upper arch intrusion, usually the best quality bone can be found in the area surrounding the mid-sagittal suture. However, placing TADs in these areas would be disadvantageous, as directly connecting the TAD to the posterior teeth would produce large, unwanted horizontal forces. These forces can have significant clinical consequences in patients with maxillary constriction, as observed in this patient. Therefore, to make the line of action of the force more vertical, it requires an appliance that allows placement of TADs in the mid-sagittal plane, but has long arms that can extend palatally to the posterior teeth, where they allow application of more vertical intrusive forces.

CTOR Intrusion plates allow the placement of TADs in good-quality bone while creating appropriate line of force application. The TADs to fixate the external plates are 2 mm in diameter, providing significant retention when placed in the sound cortical bone surrounding the mid-sagittal suture. Given the high mechanical retention, increasing the TAD length is unnecessary, which could significantly reduce the risk of penetrating the nasal cavity. The external plate is connected to the TADs by two small caps that can be removed at any time to adjust CTOR Intrusion Plate outside the mouth without removing the TADs (Figure 8).

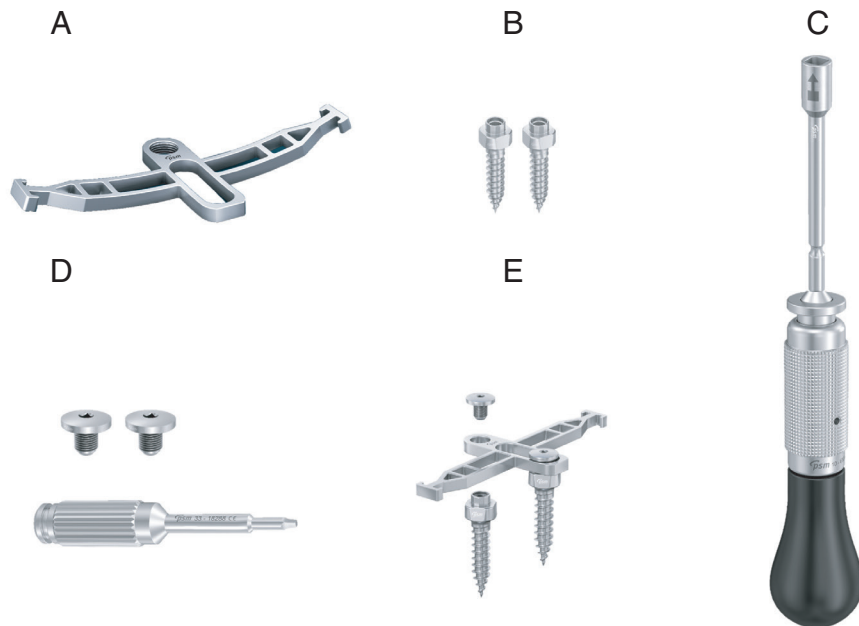


Figure 8: CTOR Plates and insertion kit. In this patient, we used a CTOR Intrusion Plate (A), secured to the plate with two TADs (B), 2 mm thick and 7 mm long. These TADs can be inserted by hand instrument (C) or a slow-speed motor. Capping screws were tightened to the TAD using a magnetic handheld screw driver (D) to secure the Intrusion Plates to the TADs (E). This system allows easy removal of the plate for necessary adjustments at a later time (psm-medical.com). There are several advantages to the use of external plates compared to the use of TADs alone, including better resistance to moments and forces that may unscrew or destabilize conventional single TADs

The TAD design keeps the external plate 2 mm away from the palatal mucosa, reducing the risk of mucosal impingement. In addition, the use of 2 TAD resist moments and forces that may unscrew or destabilize conventional TADs

Expansion usually causes the posterior teeth to tilt buccally, regardless of the method used. Tilting could position the palatal cusps of the molars more occlusally and worsen the open bite. Therefore, the application of an external plate that allows the application of an intrusion force close to the palatal cusps of posterior teeth could be very useful controlling this side effect. Force from the external plate was applied to the posterior teeth by a power chain or power tread connected to the lingual buttons positioned on the lingual surface of the posterior teeth (Figure 9A and B).

The intrusion force at the beginning of treatment was applied only to the teeth that were in occlusal contact with the mandibular teeth, requiring a segmental arch setup that connected only those upper posterior teeth. As the open bite improved and more posterior teeth gained occlusal contacts, the application of the intrusion force was extended anteriorly, and the number of teeth engaged in the sectional wire increase. As the upper teeth gradually engaged the wire, a new center of resistance is created, allowing clockwise rotation of the occlusal plane (Figure 10). A combination of this rotation and a counterclockwise rotation of the mandible helped address the class II molar and canine relationship, which was further improved by correcting the mandibular shift observed in this case.

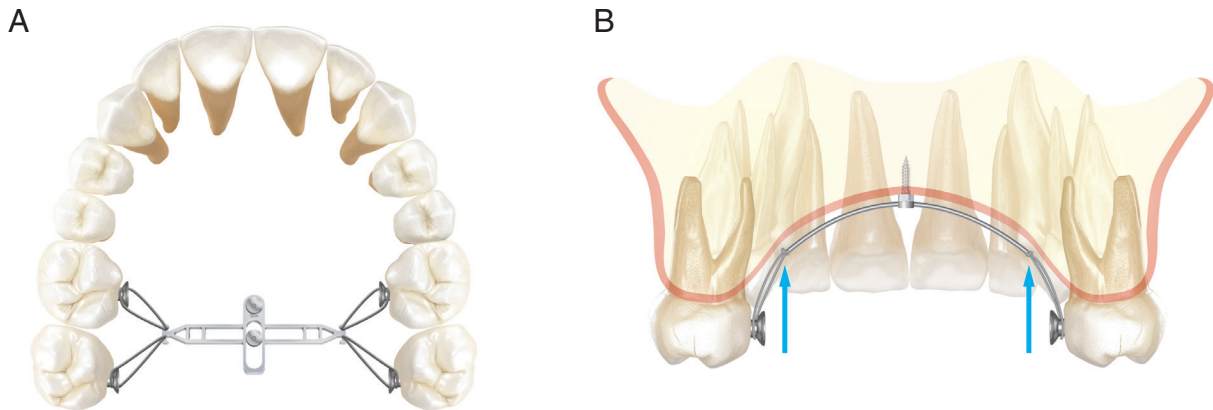


Figure 9: Schematic of CTOR Intrusion Plate used apply a force to the molars. Occlusal view schematic shows the external plate connected to the lingual buttons on the palatal surface of the molars using a power tread (A). This produces an intrusion force (straight blue arrows) close to the center of resistance of the posterior teeth (B) reducing horizontal forces applied to this teeth. Please note that these TADs have a small platform on their neck that stabilizes the external pate and prevents it from touching the palatal mucosa for improved patient comfort.

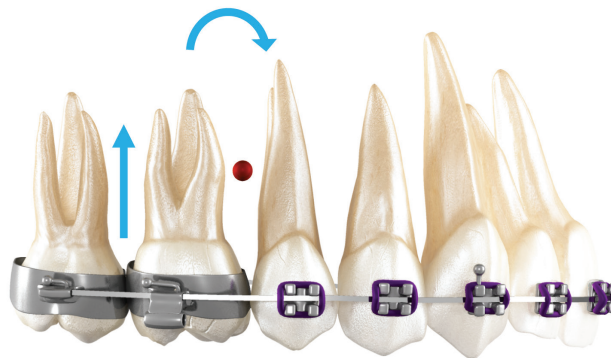


Figure 10: Application of intrusion force on posterior teeth by the CTOR Intrusion Plate produces a clockwise rotation of the occlusal plane. The palatal intrusion force (straight blue arrow) produced by the CTOR plate not only can intrude the posterior teeth, but can also cause rotation of the occlusal plane (moment represented by curved blue arrow). The effect depends on the number of teeth connected together in the dental arch, and where the center of resistance of the dental arch (red circle) is located in relation to the line of action of the force.

The patient reported significant improvement in her TMD symptoms. It should be emphasized that, in general, appliances with an anterior bite plate that disocclude the posterior teeth should not be used for long-term treatment of TMD symptoms. TMJ is considered a type III lever [7], which means loads on the condyles increase as the occlusal force travels more anteriorly. Therefore, prolonged use of an anterior bite plate can worsen TMJ discomfort. In other words, these appliances not only cannot unload the condyle but, in the long term, can significantly increase its load. At the beginning these appliances can help reduce TMD symptoms by decreasing nocturnal muscle activity, thereby reducing the load on the TMJ and reducing the patient's discomfort [4]. However, long-term use can bring discomfort back, due to the high reaction forces that appear at the condyle, especially in patients who continue to have sleep bruxism. The same phenomenon was observed in this case, where an anterior bite plate initially helped reduced TMD symptoms, but after a long period of use, the symptoms returned, especially since the patient's sleep bruxism persisted.

One challenge remains in the treatment of these patients, related to the appropriate design of retainers. The risk of sleep bruxism persists after orthodontic treatment in the majority of these cases, and therefore, patients need to wear retainers for the rest of their lives. We recommend designing a bite plate that covers all the teeth to prevent differential extrusion. In addition, we recommend the limited use of this appliance only during sleep time to reduce the possible side effects. These retainers can be made from both acrylic and soft materials, but there have been reports that soft materials can increase the risk of sleep bruxism [28, 29]. Therefore, if clinicians decide to use a soft material, the occlusal plate should be covered with hard acrylic.

Conclusion

As reported here, the application of splints can interfere with occlusal function and lead to consequences, including development of severe malocclusions. While splints are very useful tools for some patients with TMD symptoms, they should be supervised continuously, and patients should use them for only a few hours per day.

Applied Innovation

This case report emphasizes the importance of the CTOR Intrusion Plate as an innovative approach to treating open bites. CTOR Plates are very versatile tools. They can be placed by orthodontists in areas with optimal bone support to significantly simplify their biomechanics. The plates can be easily inserted and adjusted as the treatment progress demands, without compromising the stability of the TADs. At the same time, the plate's low profile is very comfortable for the patient. CTOR Intrusion Plates allow precise mechanotherapy with maximum bone anchorage, without loss of TAD stability.

References

1. Macedo CR, Silva AB, Machado MA, Saconato H, Prado GF. Occlusal splints for treating sleep bruxism (tooth grinding). *Cochrane Database Syst Rev*. 2007;2007(4):Cd005514. Epub 20071017. doi: 10.1002/14651858.CD005514.pub2. PubMed PMID: 17943862; PubMed Central PMCID: PMCPMC8890597.
2. Klasser GD, Greene CS. Oral appliances in the management of temporomandibular disorders. *Oral Surg Oral Med Oral Pathol Oral Radiol Endod*. 2009;107(2):212–23. doi: 10.1016/j.tripleo.2008.10.007. PubMed PMID: 19138639.
3. Clark GT, Beemsterboer PL, Solberg WK, Rugh JD. Nocturnal electromyographic evaluation of myofascial pain dysfunction in patients undergoing occlusal splint therapy. *J Am Dent Assoc*. 1979;99(4):607–11. doi: 10.14219/jada.archive.1979.0348. PubMed PMID: 292717.
4. Dubé C, Rompré PH, Manzini C, Guitard F, de Grandmont P, Lavigne GJ. Quantitative polygraphic controlled study on efficacy and safety of oral splint devices in tooth-grinding subjects. *J Dent Res*. 2004;83(5):398–403. doi: 10.1177/154405910408300509. PubMed PMID: 15111632.
5. Greene CS, Laskin DM. Splint therapy for the myofascial pain--dysfunction (MPD) syndrome: a comparative study. *J Am Dent Assoc*. 1972;84(3):624–8. doi: 10.14219/jada.archive.1972.0090. PubMed PMID: 4500373.
6. Rubinoff MS, Gross A, McCall WD, Jr. Conventional and nonoccluding splint therapy compared for patients with myofascial pain dysfunction syndrome. *Gen Dent*. 1987;35(6):502–6. PubMed PMID: 3481734.
7. Hylander WL. The human mandible: lever or link? *Am J Phys Anthropol*. 1975;43(2):227–42. doi: 10.1002/ajpa.1330430209. PubMed PMID: 1101706.
8. de Bont LG, Dijkgraaf LC, Stegenga B. Epidemiology and natural progression of articular temporomandibular disorders. *Oral Surg Oral Med Oral Pathol Oral Radiol Endod*. 1997;83(1):72–6. doi: 10.1016/s1079-2104(97)90094-9. PubMed PMID: 9007927.
9. Okeson JP. Nonsurgical management of disc-interference disorders. *Dent Clin North Am*. 1991;35(1):29–51. PubMed PMID: 1997356.
10. Türp JC, Komine F, Hugger A. Efficacy of stabilization splints for the management of patients with masticatory muscle pain: a qualitative systematic review. *Clin Oral Investig*. 2004;8(4):179–95. Epub 20040604. doi: 10.1007/s00784-004-0265-4. PubMed PMID: 15179561.
11. Smith SD. Muscular strength correlated to jaw posture and the temporomandibular joint. *N Y State Dent J*. 1978;44(7):278–85. PubMed PMID: 279885.
12. Seedorf H, Scholz A, Kirsch I, Fenske C, Jüde HD. Pivot appliances - is there a distracting effect on the temporomandibular joint? *J Oral Rehabil*. 2007;34(1):34–40. doi: 10.1111/j.1365-2842.2005.01557.x. PubMed PMID: 17207076.
13. Lerman MD. The hydrostatic appliance: a new approach to treatment of the TMJ pain-dysfunction syndrome. *J Am Dent Assoc*. 1974;89(6):1343–50. doi: 10.14219/jada.archive.1974.0616. PubMed PMID: 4610034.
14. Pettengill CA, Growney MR, Jr., Schoff R, Kenworthy CR. A pilot study comparing the efficacy of hard and soft stabilizing appliances in treating patients with temporomandibular disorders. *J Prosthet Dent*. 1998;79(2):165–8. doi: 10.1016/s0022-3913(98)70211-2. PubMed PMID: 9513102.
15. Keyser MMB, Lathrop H, Jhingree S, Giduz N, Bocklage C, Couldwell S, et al. Impacts of Skeletal Anterior Open Bite Malocclusion on Speech. *FACE (Thousand Oaks)*. 2022;3(2):339–49. Epub 20220314. doi: 10.1177/27325016221082229. PubMed PMID: 35903399; PubMed Central PMCID: PMCPMC9328410.
16. Khechoyan DY. Orthognathic surgery: general considerations. *Semin Plast Surg*. 2013;27(3):133–6. doi: 10.1055/s-0033-1357109. PubMed PMID: 24872758; PubMed Central PMCID: PMCPMC3805731.

17. Chang PE, Kim JY, Jung HD, Park JJ, Choi YJ. Posttreatment stability of an anterior open-bite by molar intrusion compared with 2-jaw surgery - a retrospective study. *Clin Oral Investig*. 2022;26(11):6607–16. Epub 20220712. doi: 10.1007/s00784-022-04615-6. PubMed PMID: 35821135.
18. Bueno Medeiros R, Cardoso de Araújo LF, Mucha JN, Trindade Motta A. Stability of open-bite treatment in adult patients: A systematic review. *Journal of the World Federation of Orthodontists*. 2012;1(3):e97–e101. doi: 10.1016/j.ejwf.2012.09.002.
19. Rostamzadeh S, Ghasemirad M, Gerayeli M, Abasi M, Pouresmaeliyan Roumani M, Ganjehzadeh S, et al. Radiographic Evaluation of Implant Stability and Osseointegration in Adult Orthodontic Patients. *Galen Medical Journal*. 2025;14:e3799. doi: 10.31661/gmj.v14i.3799.
20. Alikhani M, Sangsuwon C, Alansari S, Nervina JM, Oliveira S, Teixeira CC. CTOR Plates: A new invention for non-surgical treatment of complex malocclusions. *Innovation*. 2021;1(1). doi: 10.30771/2021.2.
21. Shankland WE, 2nd. Migraine and tension-type headache reduction through pericranial muscular suppression: a preliminary report. *Cranio*. 2001;19(4):269–78. doi: 10.1080/08869634.2001.11746178. PubMed PMID: 11725851.
22. Jokstad A, Mo A, Krogstad BS. Clinical comparison between two different splint designs for temporomandibular disorder therapy. *Acta Odontol Scand*. 2005;63(4):218–26. doi: 10.1080/00016350510019982. PubMed PMID: 16040444.
23. Al Quran FA, Kamal MS. Anterior midline point stop device (AMPS) in the treatment of myogenous TMDs: comparison with the stabilization splint and control group. *Oral Surg Oral Med Oral Pathol Oral Radiol Endod*. 2006;101(6):741–7. Epub 20050930. doi: 10.1016/j.tripleo.2005.04.021. PubMed PMID: 16731393.
24. Magnusson T, Adiels AM, Nilsson HL, Helkimo M. Treatment effect on signs and symptoms of temporomandibular disorders--comparison between stabilisation splint and a new type of splint (NTI). A pilot study. *Swed Dent J*. 2004;28(1):11–20. PubMed PMID: 15129601.
25. Burgos-Lancero P, Ibor-Miguel M, Marqués-Martínez L, Boo-Gordillo P, García-Miralles E, Guinot-Barona C. Correction of Anterior Open Bite Using Temporary Anchorage Devices: A Systematic Review and Meta-Analysis. *J Clin Med*. 2025;14(14). Epub 20250713. doi: 10.3390/jcm14144958. PubMed PMID: 40725652; PubMed Central PMCID: PMCPCMC12294894.
26. Baumgaertel S. Quantitative investigation of palatal bone depth and cortical bone thickness for mini-implant placement in adults. *Am J Orthod Dentofacial Orthop*. 2009;136(1):104–8. doi: 10.1016/j.ajodo.2008.11.020. PubMed PMID: 19577156.
27. Gibas-Stanek M, Żabicki S, Urzędowski M, Pihut M. Evaluation of Palatal Bone Thickness at the Implantation Areas of Two Popular Bone-Anchored Distalizers-A Cone Beam Computed Tomography Retrospective Study. *Diagnostics (Basel)*. 2023;13(14). Epub 20230720. doi: 10.3390/diagnostics13142421. PubMed PMID: 37510166; PubMed Central PMCID: PMCPCMC10378256.
28. al-Quran FA, Lyons MF. The immediate effect of hard and soft splints on the EMG activity of the masseter and temporalis muscles. *J Oral Rehabil*. 1999;26(7):559–63. doi: 10.1046/j.1365-2842.1999.00421.x. PubMed PMID: 10445474.
29. Savabi O, Nejatidanesh F, Khosravi S. Effect of occlusal splints on the electromyographic activities of masseter and temporal muscles during maximum clenching. *Quintessence Int*. 2007;38(2):e129–32. PubMed PMID: 17510715.